



Dossier 12

P. LACOMBE
M. EL HAJJAM

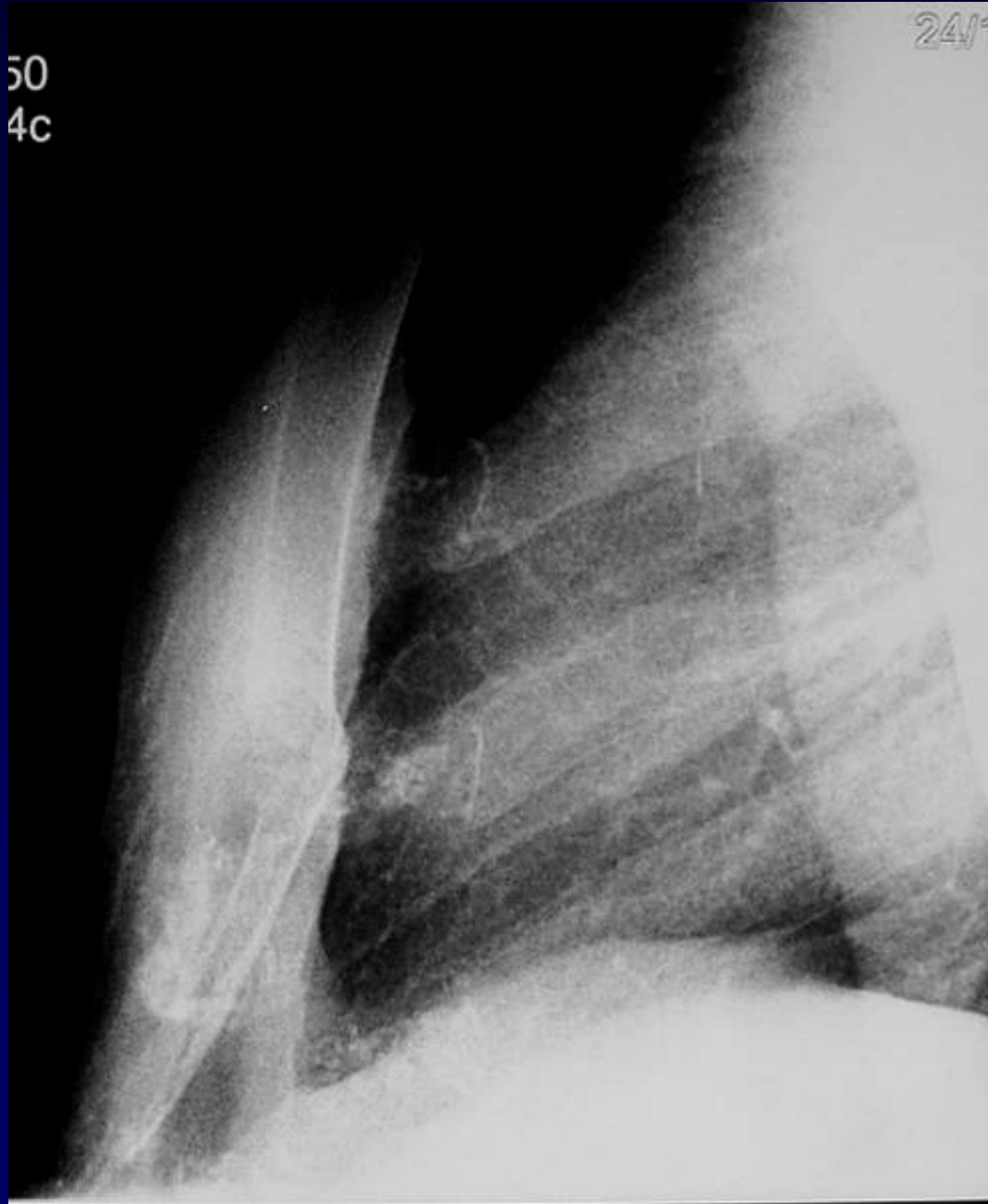
Homme de 52 ans

Choc direct sur le sternum

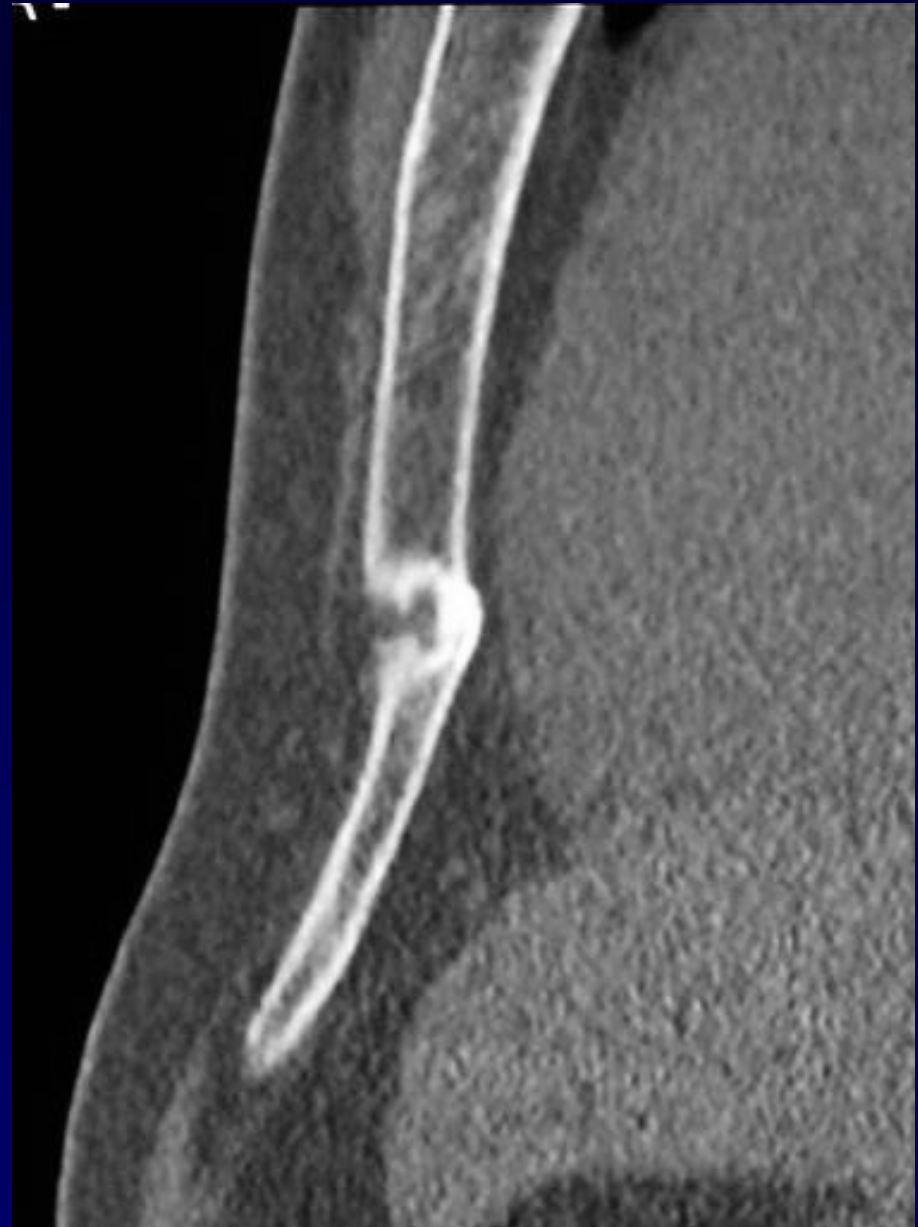
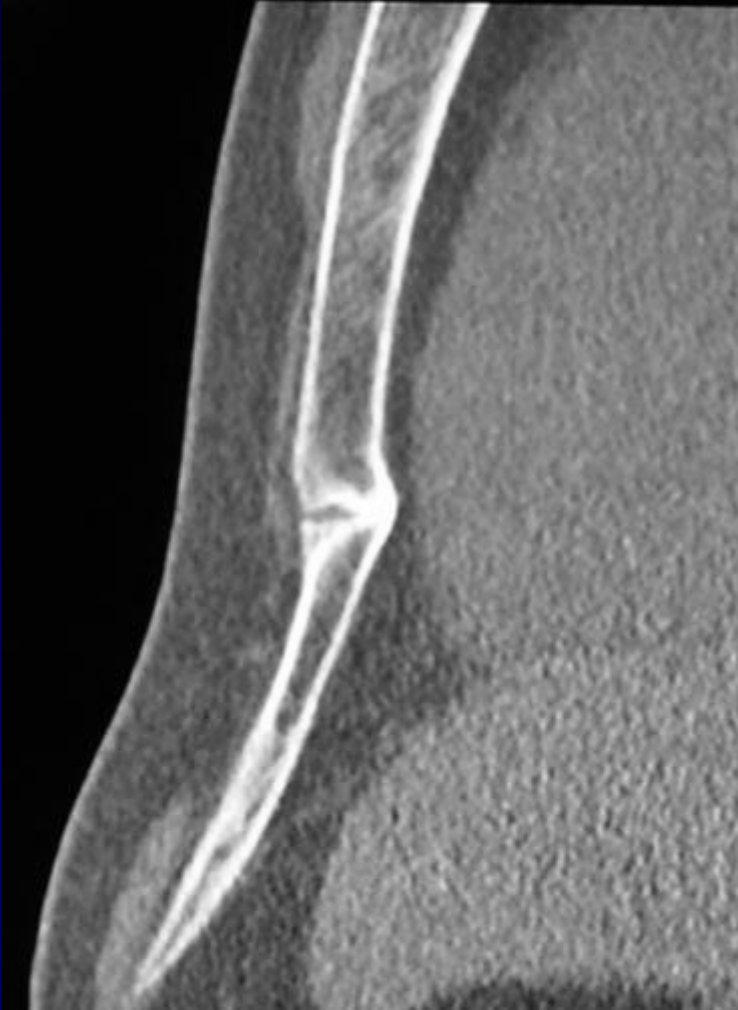
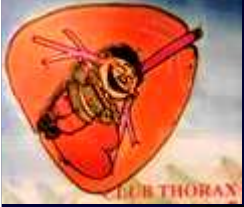50
4c

24/1



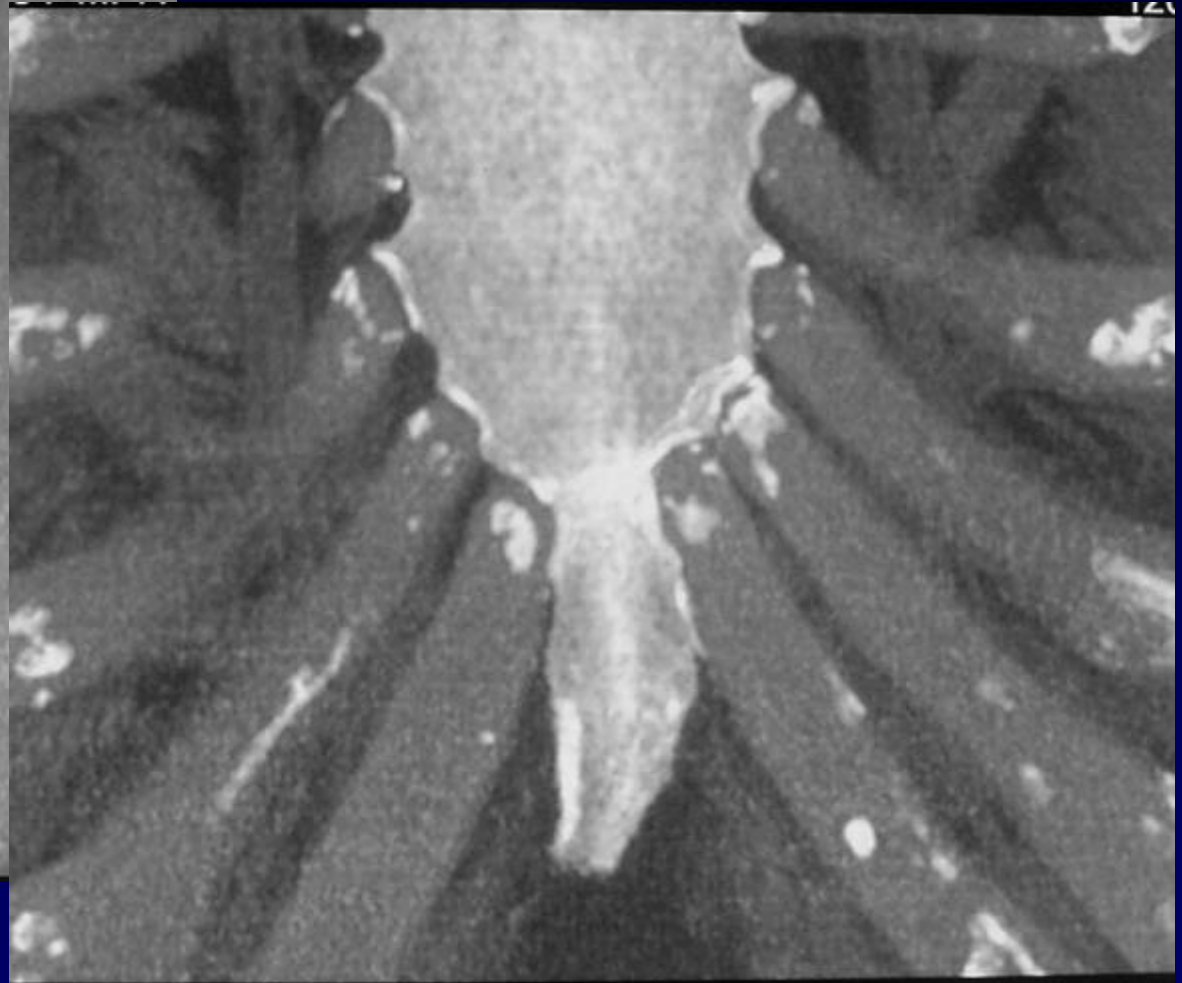
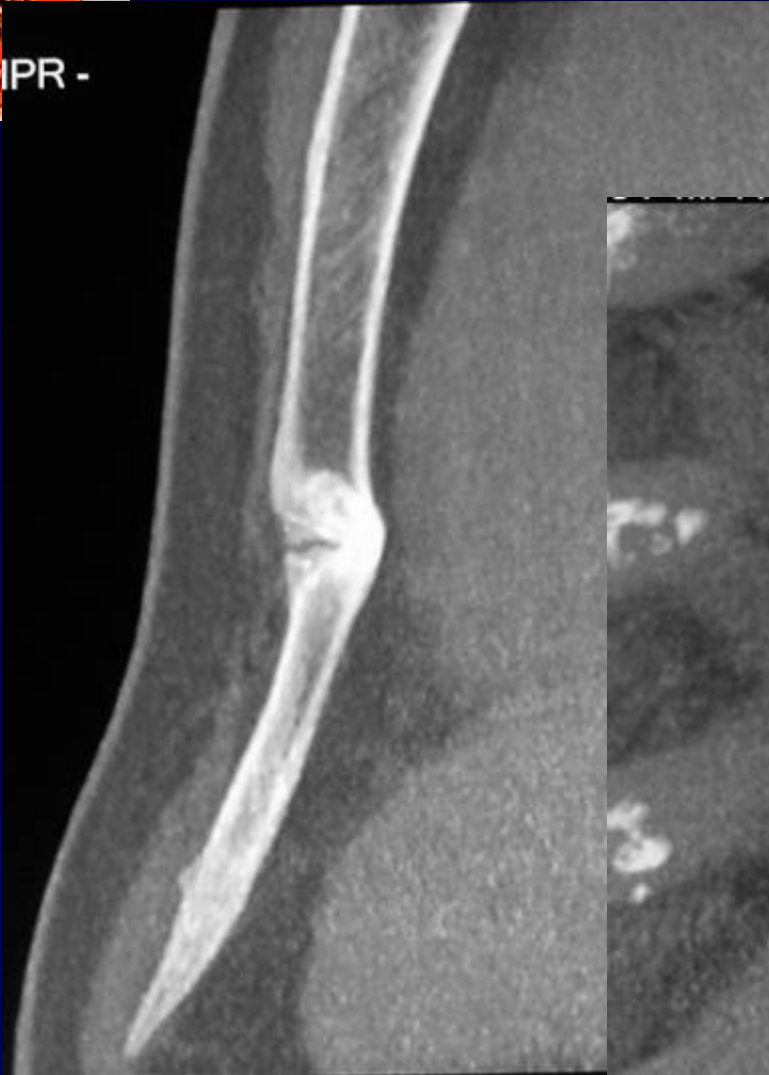**Rx sternum
profil**



TDM
MPR



IPR -



TDM
MIP



Diagnostic ?



Diagnostic

Pas de fracture sternale

Variante du normal

**Unusual partitioned xiphoid
process ***

* Référence : Theodore E Keats. Atlas of normal roentgen variants that may simulate disease. 7th edition ; p 448

Codage : Paroi - Anatomie